

## REMOVAL OF GUTTA-PERCHA FROM THE ROOT CANALS USING THREE DIFFERENT ROTARY FILES

Harleen Kaur Gill<sup>1</sup> Ajay Chhabra<sup>2</sup> Varun Jindal<sup>3</sup> Ankur Vats<sup>4</sup> Gurkirat Singh Grewal<sup>5</sup>

<sup>1</sup>PG Student, Department of Conservative Dentistry, Bhojia Dental College & Hospital, Distt. Solan, Himachal Pradesh (India)

<sup>2</sup>Professor & Head, Department of Conservative Dentistry, Bhojia Dental College & Hospital, Distt. Solan, Himachal Pradesh (India)

<sup>3</sup>Reader, Department of Conservative Dentistry, Bhojia Dental College & Hospital, Distt. Solan, Himachal Pradesh (India)

<sup>4</sup>Senior Lecturer, Department of Conservative Dentistry, Bhojia Dental College & Hospital, Distt. Solan, Himachal Pradesh (India)

<sup>5</sup>PG Student, Department of Conservative Dentistry, Bhojia Dental College & Hospital, Distt. Solan, Himachal Pradesh (India)

**Corresponding Author:**

<sup>1</sup>Mobile: 919882128103 Email: gharleen@yahoo.com

### ABSTRACT

**Received :**  
1<sup>st</sup> Sept, 2013

**Accepted:**  
10<sup>th</sup> Nov, 2013

**Available online:**  
28<sup>th</sup> Dec, 2013

In case of failed root canal treatment endodontic retreatment of the root canal system is necessary. The aim of the present study was to compare the gutta-percha removal with Protaper retreatment files (Dentsply Maillefer, Ballaigues, Switzerland), K3 (SybronEndo) and Hero Shapers (MicroMega, Besancon, France). **Method:** Thirty freshly extracted human single rooted teeth were prepared with ProTaper rotary instruments up to file F3 and filled with 30 # GP cones and AH plus sealer. The teeth were then stored for 1 week. The teeth were divided into 3 retreatment groups (n=10). The gutta-percha was removed using Protaper retreatment files, K3 and Hero Shapers. Teeth were then evaluated using radiographs. **Results:** Comparing the ratio between clean canals Protaper and K3 showed better debris removal as compared to Hero shaper. But no significant difference was found.

**Keywords:** Gutta percha, Endodontics, RC sealer

### INTRODUCTION

A certain number of cases do not respond to initial endodontic therapy for many reasons; retreatment becomes necessary. The main causes of endodontic failure are improper cleaning and filling of the root canal system (necrotic tissue, bacteria and biofilm may be identified), procedural errors, or the lack of an efficient hermetic sealing, which enables the survival of bacteria inside dentinal tubules, apical ramifications, accessory and secondary canals.<sup>1</sup> Elimination of these etiologies is essential to reestablish an environment conducive to repairing and healing.<sup>2</sup>

The endodontic failure cases can be treated in three ways: nonsurgical retreatment, surgical retreatment, or extraction. Among all these treatment alternatives nonsurgical retreatment should be considered as the first choice of treatment. Success rates for orthograde retreatment are 65% to more than 80%.<sup>3</sup>

The main goal of orthograde retreatment are regaining access to the apical foramen by complete removal of root canal filling material, thus facilitating

sufficient cleaning and shaping of complete root canal system and final obturation. Only if the filling material can be removed completely and the root canal negotiated to the apical foramen allowing thorough debridement, can the prerequisites for successful retreatment be fulfilled.<sup>4</sup>

Techniques described for gutta-percha removal include the use of hand and rotary instruments, heat carrying instruments, solvents and ultrasonics. Although numerous materials have been described for obturation of root canals, gutta-percha in combination with a sealer is the most frequently used material.<sup>5</sup> Removal techniques are dependent upon canal size and anatomy, canal third, well condensed or aged gutta-percha, quantity of gutta-percha present and whether the existing gutta-percha is over or under-extended relative to the apical foramen.<sup>6</sup>

The ability to remove root filling materials is oftentimes most difficult due to anatomical constraints that may prevent thorough cleaning. While a wide range of anatomical complexities may be encountered during root canal retreatment/revision

procedures, including fins, webs, cul-de-sacs, isthmuses, ribbon- and dumbbell-shaped canals, dilacerations, and C- and S-shaped canals, the most commonly encountered anatomical challenge may be the curved canal. Furthermore, clinicians often forget that even though the roots may appear straight on a radiograph, curvatures in the third dimension are quite common.<sup>2</sup>

Specific rotary NiTi file designs for root filling material removal are the ProTaper Universal Rotary Retreatment System (PTUS, DentsplyMaillefer, Ballaigues, Switzerland). The manufacturers claim that this systems, in addition to shaping and finishing the root canal, is also effective in the removal of the root filling material from root canals. This systems has been evaluated as to their ability to remove the previous root filling materials and retained debris from canals systems, with neither system demonstrating 100% effectiveness.<sup>7</sup> K3 rotary system has a unique three cutting edge design which provides an active file as opposed to the old 'passive' files. Active files are the 3rd generation endodontic files which have greater cutting power and better debris removal. Hero Shapers has been used in retreatment of incisor teeth and a number of studies have shown its effectiveness and safety for root canal shaping.<sup>2</sup>

(I am performing this study as no study has been conducted so far to compare these three files).

## **MATERIALS AND METHOD**

Thirty freshly extracted human single rooted teeth were collected from the department of oral and maxillofacial surgery, Bhojia Dental College, Baddi and were stored in purified filled water. In all the samples, the clinical crowns were sectioned horizontally before cleaning and shaping of the root canal in order to keep similar length of all the samples which was 14 mm from the apex. Mesiodistal and buccolingual radiographs were taken to confirm that the curvature of the root canal was <10.

## **CLEANING AND SHAPING**

The pulp chambers were accessed using a diamond bur in a high-speed handpiece. A size 10 K-file was inserted into the canal until it was visible at the apical foramen, and the working length was determined to be 1 mm short of this position. ProTaper rotary

instruments were used at 300 rpm in pecking motions to prepare the canals to the full WL with endomotor up to file F3. At each instrument change, the canal was irrigated with 2 ml 3% NaOCl. When the instrumentation was complete, the canal was irrigated with 17% EDTA for 1 minute to remove the smear layer.

## **CANAL FILLING**

The canals were dried using paper points size 30 (Dentsply De Trey, Konstanz, Germany) and filled with 30 no GP cones and AH plus sealer. The teeth were then stored in 100% humidity at 37 degree C for 1 week.

## **RETREATMENT TECHNIQUE**

The 30 specimens were randomly divided into 3 retreatment groups (Pro-Taper Universal, SybronEndo K3, and Hero Shapers; n = 10 each). A No. 3 Gates-Glidden drill (Dentsply Maillefer) was used to remove the coronal 2mm of the root canal filling in the 30 retreatment specimens. To soften the gutta-percha, 0.5 mL xylene solvent was placed on the filling material. In group 1 specimens, the ProTaper Universal System was used with a crown-down technique in the following sequence: F3 (size 30, 0.09–0.05 taper), F2 (size 25, 0.08–0.055 taper), and F1 (size 20, 0.07–0.055 taper). The root canal was reinstrumented with F2 and F3 files to reach the working length. Each canal was irrigated with 2 mL 2% NaOCl between each instrument using a syringe and a 27-gauge needle.

In group 2 specimens, the SybronEndo K3 system was used in the following sequence: a size 30 file with 0.12 0.10, 0.08, 0.06, and 0.04 tapers. The root canal was reinstrumented with the 0.04 taper to reach the working length. Instruments were discarded when they were fractured or distorted but otherwise remained in use. Retreatment was considered to be complete when no additional filling material could be removed.

In group 3 specimens, the Hero Shaper files were used in the following sequence: a size 30 no. file with 6% and 4% taper followed by 25 no. file with with

6% and 4% followed by 20 no. file with with 6% and 4% taper.

**RADIOGRAPHIC TECHNIQUE:**

A radiographic technique was used to assess cleanliness of canals. The radiograph was taken with paralleling technique. The percentage of the residual gutta-percha-occupied area was calculated, and the canal cleanliness was scored as follows: score 0, no residual gutta-percha observed; scores 1= <25% debris, 2= 25-50% debris ; 3= >50% debris. The score was done using the Adobe Photoshop Elements Language Version: 10.

**CLEANLINESS OF THE ROOT CANAL WALLS**

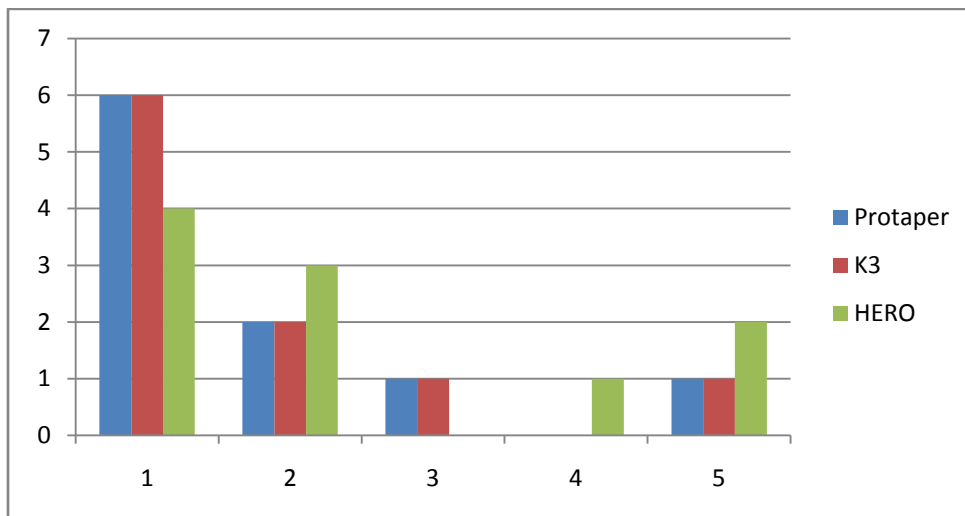
Results of the investigation of root canal cleanliness are summarized in Table 1. With Protaper and K3 6 of 10 root canals could be cleaned completely. Both showed 2 of 10 teeth where the remaining debris was 10% and only one teeth where the debris was >30%. Both protaper and K3 showed similar results. Both these showed good canal cleanliness followed by Hero shaper. Hero shaper showed only 4 of 10 root canals that were cleaned completely. 2 of 10 showed > 30% debris.

Comparing the ratio between clean canals Protaper and K3 showed better debris removal as compared to Hero shaper. But no significance difference was found. (Graph 1)

**RESULTS**

**Table 1: Results of Evaluation of Root Canal Cleanliness**

SCORE	AMOUNT OF GP REMAINING	PROTAPER	K3	HERO
1	NO	6	6	4
2	<10%	2	2	3
3	<20%	1	1	0
4	<30%	0	0	1
5	>30%	1	1	2



Graph 1: Showing evaluation of root canal cleanliness

## DISCUSSION

The retreatment can be accomplished by various instruments and techniques, *i.e.*, stainless steel, hand files, heat, ultrasonic, laser, and rotary instruments with and without the aid of solvents. In many cases, the combined use of different techniques may be the most efficient and time saving method.<sup>3,8-9</sup>

The criteria for completion of retreatment may be no evidence of gutta-percha or sealer on the files or paper points<sup>10</sup> and evaluation of post-treatment radiographs.<sup>5</sup>

Radiographic technique has successfully been used in the past to compare canals pre- and postoperatively.<sup>11</sup> A previous *ex vivo* study showed that radiographic examination provided an over optimistic impression of cleanliness compared with examination of vertically split roots. It has been previously demonstrated that it is almost impossible to remove all traces of gutta-percha/sealer from the canal walls.<sup>3,12</sup> This was also evident in the present study.

Previous studies have found no significant difference between retreatment NiTi instruments in terms of the amount of filling material left within root canals.<sup>3,11,13,14</sup> Similarly, no significant difference has been observed in the amount of filling material left within root canals by the ProTaper Universal System and the K3 System. Hero shapers have showed to remove less filling material as compared to protaper universal system and K3. But no significance difference was found.

## REFERENCES

1. Julia Elis Johann, Josuémartos, Luiz Fernando Machado Silveira and Francisco Augusto Burkert Del Pino. Use of organic solvents in Endodontics: a review. ClinPesq. Odontol 2006 July;2:393-99
2. Santhoshini Reddy, Prasanna Neelakantan, Mohammad Ali Saghiri, Mehrdad Lofti, Chandragiri Venkata Subbarao et al. Removal of Gutta-Percha/Epoxy Resin Sealer from Severely Curved Canals: An In Vitro Study. International Journal of Dentistry 2011 Article ID 541831, 6 pages.
3. Raju Chauhan, AP Tikku, Anil Chandra. Detection of residual obturation material after root canal retreatment with three different techniques using a dental operating microscope and a stereomicroscope : An in vitro comparative evaluation. J Conserv Dent 2012;15:218-22.
4. Bharathi G Chacko Y and Lakshminarayanan L. An in-vitro analysis of gutta-percha removal using three different techniques. Endodontology 2002;14:41-45
5. M. Hülsmann & S. S Totz. Efficacy, cleaning ability and safety of different devices for Gutta-percha removal in root canal retreatment. International Endodontic Journal 1997;30:227-233.
6. Ladley RW, Campbell AD, Hicks ML, Li SH. Effectiveness of halothane used with ultrasonic or hand instrumentation to remove gutta-percha from the root canal. J Endod 1991;17:221-224.
7. V. Giuliani, R. Cocchetti and G. Pagavino. Efficacy of protaper universal retreatment files in removing filling materials during root canal treatment. Journal of endodontics 2008;34(11):1381-84
8. Teplitzky Pe, Rayner D, Chin I, Markowsky R. Gutta-percha Removal utilizing GPX instrumentation. Journal of the Canadian Dental Association 1992;58:53-8
9. Friedman S, Stabholz A, Tamse A. Endodontic retreatment— case selection and technique. Part 3: Retreatment techniques. Journal of Endodontics 1990;16:543-9
10. Betti LV, Bramante CM. Quantic SC rotary instruments versus hand files for gutta-percha removal in root canal retreatment. Int Endod J 2001;34:514-9.
11. J.J. Ferreira, J.S. Rhodes & T.R. Pitt Ford. The efficacy of gutta-percha removal using profiles. Int Endod Journal 2001;34:267-274
12. J.F. Schirrmeister, P. Hermanns, K.M. Meyer, F. Goetz & E. Hellwig. Detectability of residual Epiphany and gutta-percha after root canal retreatment using a dental operating microscope and radiographs- an *ex vivo* study. International Endodontic Journal 2006; 39:558-565
13. F. Baratto Filho, E.L. Ferreira and L.F. Fariniuk. Efficiency of the 0.004 taper Profiles during the retreatment of gutta-percha filled root canals. International Endodontic Journal 2002;35:651-654
14. A. Mollo, G. Botti, N. Prinipi Goldoni, E. Paragliola, M. Chazine et al. Efficacy of two Ni-Ti systems and hand files for removing gutta-percha from root canals. International Endodontic Journal 2012;45:1-6.

Source of Support: Nil, Conflict of Interest: None Declared