

MISSED CANALS CAN NEVER BE MISSED- CT IN ENDODONTICS: A SERIES OF CASE REPORTS

Devendra Chaudhary¹, Niti Shah², Abhishek Bansal³, Navneet Kukreja⁴, Hitesh Nagarth⁵

¹Professor & Head, Department of Conservative Dentistry & Endodontics, Maharaja Ganga Singh Denal College, Rajasthan, India

²PG Student, Department Of Conservative Dentistry & Endodontics, MM College of Dental Sciences & Research Haryana, India

³Reader, Department of Conservative Dentistry & Endodontics, MM College of Dental Sciences & Research, Haryana, India

⁴Professor, Department of Conservative Dentistry & Endodontics, MM College of Dental Sciences & Research, Haryana, India

⁵PG Student, Department of Conservative Dentistry & Endodontics, MM College of Dental Sciences & Research, Haryana, India

ABSTRACT

Aberrations in the root canal anatomy are a commonly occurring phenomenon. A thorough knowledge of the basic root canal anatomy and its variations is necessary for successful completion of the endodontic treatment. The maxillary molars has fascinated researchers and clinicians for a variety of reasons. Endodontically, these are the most misunderstood teeth, and presents a variety of considerations for the treating practitioner. This case report presents the endodontic management of a maxillary first molar with five roots and five canals and another case of maxillary third molar with four canals. The clinical detection of the five canals was made using loupes and confirmed using computed tomography (CT) scanning. This report serves to remind clinicians that such anatomical variations should be taken into account during endodontic treatment of the maxillary molars.

Key words: Maxillary First Molar, Five Root Canals, Maxillary Third Molar, CT Scan

INTRODUCTION

The variability of root canal morphology of multirouted teeth presents a constant challenge to endodontic diagnosis and successful endodontic therapy.¹ Therefore, a thorough knowledge of root and root canal morphology and a good anticipation of their possible morphologic variations are essential and will help to reduce endodontic failure caused by incomplete root canal preparation and obturation.²

The Maxillary molars are the most treated and least understood teeth with the highest endodontic failure due to undetected extra canals.³ Pecora et al studied the internal anatomy of 370 maxillary molars by diaphanisation and found that the maxillary first, second and third molars displayed three canals in 75%, 58% and 68% of the teeth respectively, while there were four canals in 25% of maxillary first molars, in 42% of second molars and in 32% of third molars. The fourth canal was found in the mesio-buccal root of the teeth in 100% of these cases.⁴

The morphology and anatomy reviewed in the literature shows the maxillary first molar with great variations in anatomical configuration,⁵ ranging from one to eight root canals.⁶ The incidence of five canals reported is as low as 2.25%⁷ and 2.4%.⁸ The incidence of six canals goes down to 0.31%⁹ to 0.88%.¹⁰

Morphology of third molars has been described as unpredictable. However restorative, prosthodontic, and orthodontic considerations often requires endodontic treatment of third molars in order for them to be retained as functional components of the dental arch. Jozo Cosic found that 75% of the maxillary third molars had 3 canals, 10.7% had 4 canals, 7.1% had one canal, and 7.1% had two canals.¹¹

Root canal anatomy is studied by both in vivo (clinical) and in vitro (laboratory) methods. The techniques used in clinical studies include inspection during endodontic treatment with or without magnification tools, radiography, and review of patient records. Currently, technologic advances have been

Corresponding Author:
Devendra Chaudhary
E-mail: hellodrdc@gmail.com
Received: 29th April 2015
Accepted: 15th July 2015
Online: 10th September 2015

developed allowing a study that is more accurate, non-destructive and feasible in-vivo.¹ The laboratory methods used to analyze root canal morphology include direct observation, macroscopic sectioning, clearing techniques, filling and decalcification, contrasting media (hupaque), conventional radiographs, Micro-Computed Tomography techniques and Scanning Electron Microscopic (SEM) observation of pulpal floor.¹²

Conventional intra-oral periapical radiographs and digital radiography are an important diagnostic tool in Endodontics for assessing the canal configuration. Nevertheless, it is not completely reliable owing to its inherent limitation for being two dimensional in nature.¹³ Recently, newer diagnostic methods such as computed tomography (CT) and Spiral (SCT) or Helical CT has overcome the disadvantages of radiographs by producing a three-dimensional (3D) image. These imaging techniques have emerged as a powerful tool for evaluation of root canal morphology.¹⁴ Tachibana and Matsumoto¹⁵ in their study concluded that CT scans allowed the observation of the morphology of the root canals, the roots, and the appearance of the tooth in every direction, and it also permits its 3D reconstruction.

The present case report discusses two such cases having 5 root canals in maxillary first molar and 4 root canals in maxillary third molar which reported to the Department of Conservative & Endodontics, MM College of Dental Sciences & Research, Mullana, Ambala, India. The diagnosis was made using Digital radiovisiography (RVG) and confirmed with CT Scan.

Case Report 1

A 26 year old female patient undergoing orthodontic treatment reported to the department of conservative dentistry and endodontics with a chief complaint of pain on mastication in upper right back tooth region since 2 weeks. Electric pulp testing gave a delayed response. A preoperative radiograph revealed periodontal ligament space widening and loss of lamina dura in relation to the mesiobuccal root (Figure 1A). From the clinical and radiographic findings, a diagnosis of primary periodontic and secondary endodontic lesion was made and endodontic treatment was suggested to the patient.

Radiographic evaluation of the involved tooth did not indicate any variation in the canal anatomy (Figure 1A). The tooth was anesthetized with 1.8 mL (30 mg), 2% lignocaine containing 1:200,000 epinephrine. An endodontic access cavity was established. Clinical examination with a DG-16 endodontic explorer (Hu-Friedy, Chicago, IL) revealed the following root canal anatomy: mesiobuccal canal, distobuccal canal, large oval shaped palatal canal and an additional opening 3mm from the distoobuccal canal along the fusion lines joining the distobuccal and the palatal canal (Figure 1 B).

On subsequent visit when the chamber was re-entered and flushed with 3% sodium hypochlorite, a new brown spot was observed 0.5mm from the mesioobuccal canal along the fusion line connecting mesioobuccal and the palatal orifice. K files and H files were inserted into all the openings. During the course of instrumentation it appeared that two files entered into the mesiobuccal root, one file entered the palatal root and two files went in the distobuccal direction. Digital RVG was taken with 0 and 20 degree horizontal angulations. The two mesial canals in the mesiobuccal root were labeled as Mb1, Mb2 and the two canals in the distobuccal root as Db1 and Db2 and one P canal in palatal root (Figure 1 C).

To confirm this unusual morphology, it was decided to perform CT imaging of the tooth. An informed consent was obtained from the patient, and a multislice CT scan of the maxilla was performed (Phillips ingenuity spiral CT). CT Scan slices were taken at 0.67mm thickness with increment of 0.33mm at 120 Kv, 150 mAs/ slice with pitch of 0.203 and collimation of 64 × 0.625 at a rotation time of 0.55secs. Then reconstruction analysis was done with Denta Scan software provided by Philips.

The involved tooth was focused, and the morphology was obtained in transverse, axial, and sagittal sections of 0.5-mm thickness. CBCT images provided valuable information regarding the canal configuration and confirmed the five canals that were not clearly seen in the conventional radiograph.

The following sections were taken : Axial slice – cervical section (Figure 2A) Axial slice – apical section (Figure 2 B) Occipital condylar view – coronal section (figure 2 C) Occipital condylar view – apical section (Figure 2 D).

At the second appointment, the patient was asymptomatic. After administering 1.8 mL (36 mg) 2% lignocaine with 1:200,000 epinephrine (Xylocaine), cleaning and shaping was performed using ProTaper nickel-titanium rotary instruments (Dentsply Maillefer) with a crowdown technique. Irrigation was performed using normal saline, 2.5% sodium hypochlorite solution, and 17% EDTA; 2% chlorhexidine digluconate was used as the final irrigant. The canals were dried with absorbent points

(Dentsply Maillefer), master cone radiograph (Figure 1D) taken and obturation was performed using cold lateral compaction of gutta-percha (Dentsply Maillefer) and AH Plus resin sealer (Maillefer, Dentsply, Konstanz, Germany) (Figure 1E). The tooth was then restored with a posterior composite resin core (P60; 3M Dental Products, St Paul, MN). The patient was advised a full-coverage porcelain crown and was asymptomatic during the follow-up period of 3 months.

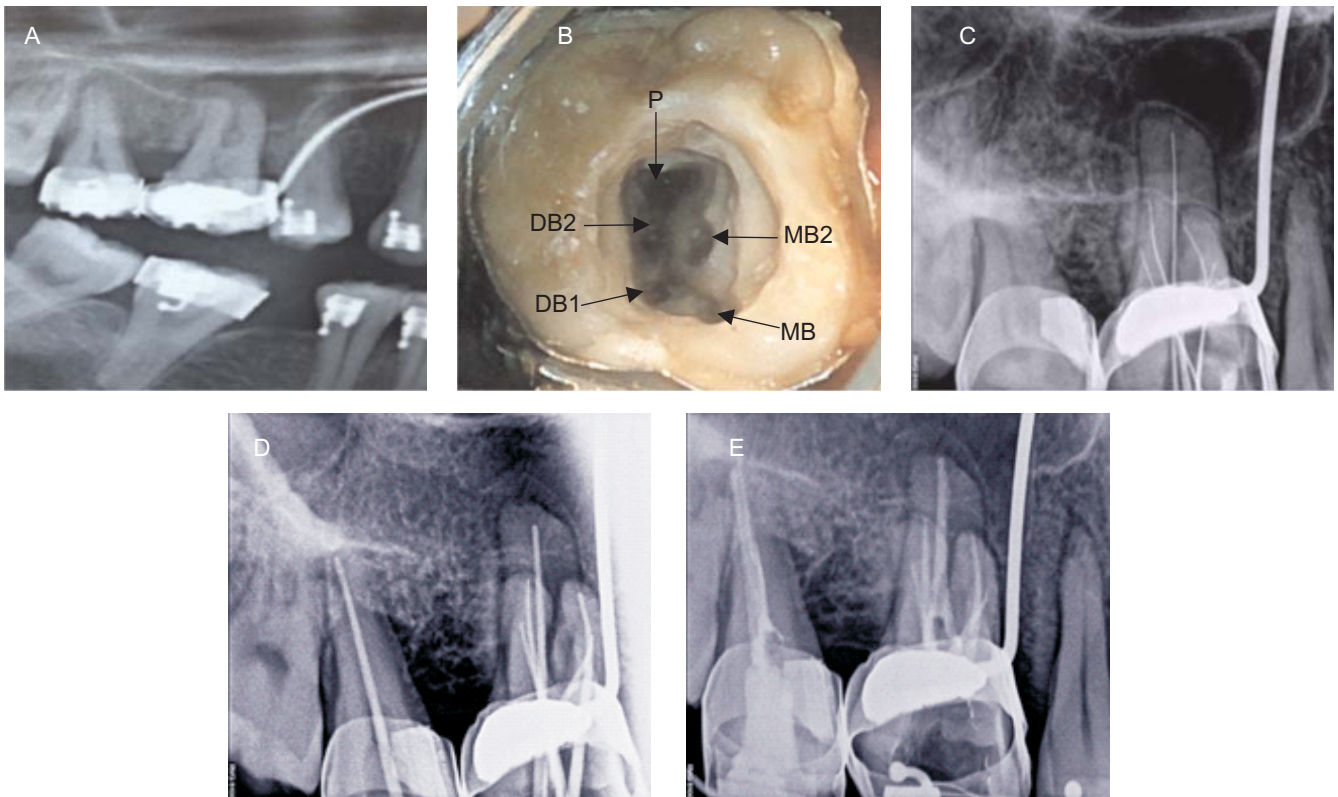


Figure 1 A: Preoperative radiograph of #3, B: Access opening showing five root canal orifices, C: Working length radiograph of #3 in eccentric angulation, D: Master cone radiograph, E: Postobturation radiograph.

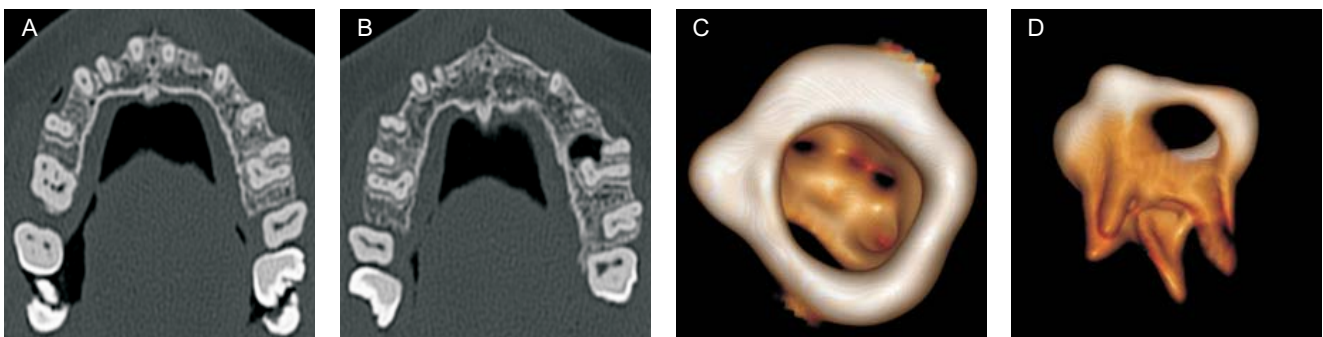


Figure 2A: Axial slice – cervical section, B: Axial slice – apical section, C: Occipital condylar view – coronal section, D: Occipital condylar view – apical section

Case Report 2

A 30 yr old female patient reported to the department of Conservative dentistry & endodontics with a chief complaint of pain along with sensitivity to hot & cold in right upper back tooth region. On clinical examination, tooth was found to be grossly carious and was tender on percussion. A preoperative radiograph (Figure 3A) was taken, which revealed radiolucency approaching pulp along with loss of lamina dura and widening of periodontal ligament space. On the basis of clinical & radiographic findings a diagnosis of chronic irreversible pulpitis was made and patient was advised to undergo endodontic therapy.

The tooth was anesthetized with 1.8 ml (30 mg) 2% lignocaine containing 1:200,000 epinephrine. An endodontic access cavity was established (Figure 3 B). Clinical examination with a DG-16 endodontic explorer (Hu-Friedy, Chicago, IL) revealed the following root canal anatomy : mesiobuccal canal, distobuccal canal, large oval shaped palatal canal and an additional opening 3mm from the mesiobuccal canal along the fusion lines joining the mesiobuccal and the palatal canal.

K files and H files were inserted into all the openings. During the course of instrumentation it appeared that

two files entered into the mesiobuccal root. On extensive visual and radiographic examination there was a second distobuccal canal. Digital RVG was taken with 0 and 20 degree horizontal angulations. The two mesial canals in the mesiobuccal root were labelled as Mb1, Mb2 and the two canals in the distobuccal root as DB1 and DB2 and one canal in palatal root (Figure 3 C).

At the second appointment, the patient was asymptomatic. After administering 1.8 mL (36 mg) of 2% lignocaine with 1:200,000 epinephrine (Xylocaine), cleaning and shaping was performed using MTWO nickel-titanium rotary instruments (VDW) with a crowdown technique. Irrigation was performed using normal saline, 2.5% sodium hypochlorite solution, and 17% EDTA; 2% chlorhexidine digluconate was used as the final irrigant. The canals were dried with absorbent points (Dentsply Maillefer), master cone radiograph was taken (Figure 3D) and obturation was performed using cold lateral compaction of gutta-percha (Dentsply Maillefer) and AH Plus resin sealer (Maillefer, Dentsply, Konstanz, Germany) (Figure 3E). The tooth was then restored with a posterior composite resin core (P60; 3M Dental Products, St Paul, MN). The patient was advised a full-coverage porcelain crown and was asymptomatic during the follow-up period of 1 month.

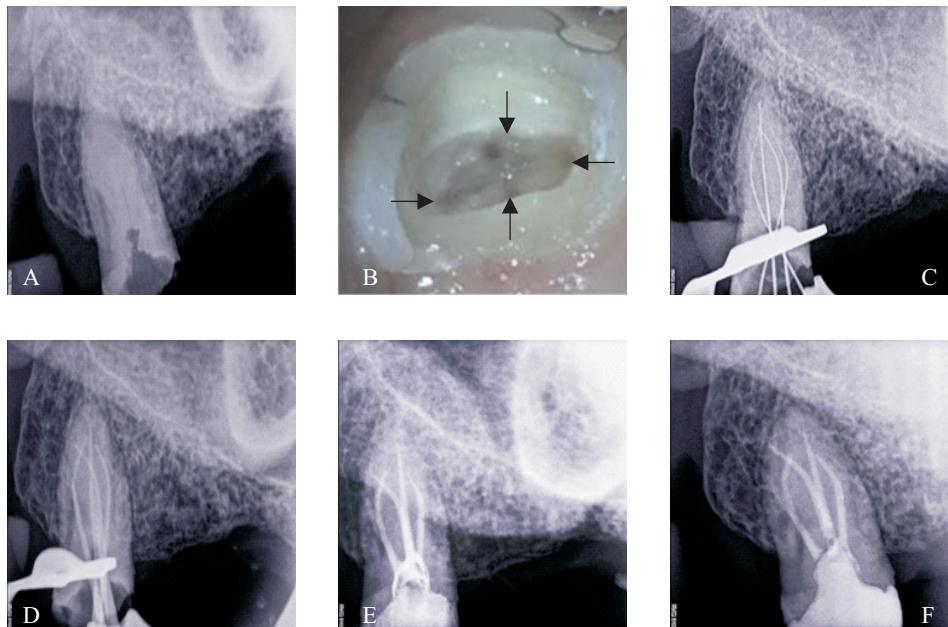


Figure 3A: Preoperative radiograph, B: Access cavity preparation showing 4 canal orifices, C: Working length radiograph, D: Master cone radiograph, E: Postobturation radiograph, F: Post endodontic restoration

DISCUSSION

Anatomical aberrations are not uncommon in maxillary first molars ranging from one to eight canals.⁵ With such a varied morphology, suspicion of iatrogenic or pathological perforation arises, especially when new brown bleeding spots are seen at unexpected locations. In such situations of doubt, various methods have been discussed in the past by many authors^{16,17-22} such as additional off-angle radiographs (at least 3 radiographs at varying horizontal angles), use of computed tomography, use of magnification (loupes and dental operating microscopes), examination of dentinal map minutely and use of DG 16 to explore the floor of the pulp chamber, looking for hemorrhagic spots (indicate the presence of extra canals), performing champagne or bubble test with sodium hypochlorite, staining the pulp chamber with dye (eg, 1% methylene blue), use of ultrasonic tips, special round burs, and thin tapering finishing burs to remove a small amount of tooth structure or calcification and trough the line angles of the pulp chamber, modification of the conventional outline form to include the extra canals, ensure adequate straight-line access to improve visibility.

Radiographic examination is an essential component of the management of endodontic problems. The amount of information gained from conventional radiographs and digitally captured periapical radiographs is limited by the fact that the three-dimensional anatomy of the area being radiographed is compressed into a two-dimensional image.²³ Newer diagnostic methods such as computerized axial tomography (CT) scanning greatly facilitate access to the internal root canal morphology. One distinct advantage of CT scanning over the conventional radiograph is that it allows the operator to look at multiple slices of tooth roots and their root canal systems.²³ Robinson et al²⁴ reported that CT images identified a greater number of morphologic variations than panoramic radiographs. Although conventional CT scans produce a high level of detail in the axial plane, it is essential that the radiation dose is kept as low as reasonably achievable.²⁵⁻²⁶

The Cone Beam Computed Tomography was introduced in endodontics in 1990. The major advantages of CBCT scanning over the conventional CT scans are x-ray beam limitation, rapid scan time,

and effective dose reduction. Even though the use of CBCT scanning involves less radiation than conventional CT scanning, the radiation dose is still higher than regular conventional intraoral radiographs. Published reports indicate that the effective dose (E) radiation is significantly reduced to an average of 36.9 to 50.3 mSv, a reported radiation dose equivalent to that needed for 4 to 15 panoramic radiographs. Patient's radiation exposure to a conventional CT is approximately 100 to 300 mSv for maxilla and 200 to 500 mSv for the mandible, whereas the radiation exposure (for both maxilla and mandible) to CBCT scanning is 34 to 102 mSv.²⁷⁻³⁰

At this point of time, CBCT scanning is limited to major metropolitan areas and is very expensive. Thus in our study due to availability and economic factors we decided to go for Helical CT. In future with rapid technological advancement with respect to reduced radiation dose and enhanced image quality, it may be possible to use Computed Tomography as one of the routine diagnostic tools for accurate diagnosis and treatment planning.

In the present case, CT scanning was used for a better understanding of the complex root canal anatomy. CT axial images confirmed the presence of three roots and five root canals, namely mesiobuccal1 (MB1), mesiobuccal2 (MB2), distobuccal1 (DB1), distobuccal2 (DB2), & palatal.

CONCLUSION

The present case report discusses the endodontic management of an unusual case of a maxillary first molar with four roots and five canals and a maxillary third molar with 4 canals and also highlights the role of CT scanning as an objective analytic tool to ascertain root canal morphology.

REFERENCES

1. Maggiore F, Jou YT, Kim S. A six canal maxillary first molar: case report. *Int Endod J* 2002; 35:486-491.
2. Holderrieth S, Gernhardt CR. Maxillary Molars With Morphologic Variations of the Palatal Root Canals: A Report of Four Cases. *J Endod* 2009; 35(7):1060-65.
3. Vertucci F, James E, Haddix, Britto L. Tooth morphology and Access cavity preparation. In, Cohen S, Hargreaves K(ed). *Pathways of the Pulp*, 8th edition. New Delhi, Elsevier, 1998;148-232.
4. Pécora JD, Woelfel JB, Sousa Neto MD, Issa EP. Morphology study of the maxillary molars part II: internal anatomy. *Braz Endod J* 1992; 3: 53-7.

5. Carlsen O. Dental morphology. Copenhagen: Munksgaard 1987.
6. Kottor J, Velmurugan N, Surendran N. Endodontic management of maxillary first molar with eight root canal systems evaluated using Cone Beam Computed Tomography scanning: a case report. *J Endod* 2011;37:715-719.
7. Gray R. The Maxillary first molar. In: Bjomdal A, Skidmore E, eds. *Anatomy and morphology of the human teeth*. Iowa City: University of Iowa College of Dentistry 1983; 31-40.
8. Acosta Vigouroux SA, Trugeda Bosaans SA. Anatomy of the pulp chamber floor of the permanent maxillary first molars. *J Endod* 1978;4:214-219.
9. Zheng Q, Wang Y, Zhou X, Wang Q, Zheng G, Huang D. A Cone Beam Computed Tomography study of Maxillary first permanent molar root and canal morphology in a Chinese population. *J Endod* 2010; 36 :1480-1484.
10. Martinez-Berna A, Ruiz-Badanelli P. Maxillary first molars with six canals. *J Endod* 1983;9:375-381.
11. Cosic J ,Galic N, Njemirovskij V, Vodanovic M. Root Canal Anatomy of Third Molars. PEF IADR. <http://iadr.confen.com>
12. Seidberg BH, Altman M, Guttuso J. Frequency of two mesiobuccal root canals in maxillary permanent first molars. *J Am Dent Assoc* 1973;87:852-856.
13. Hildebolt CF, Vannier MW, Pilgram TK, Shrout MK. Quantitative evaluation of digital dental radiograph imaging systems. *Oral Surg Oral Med Oral Pathol* 1990;70:661–668.
14. Peters OA. Current challenges and concepts in the preparation of root canal systems: a review. *J Endod* 2004;30:559–567.
15. Tachibana H, Matsumoto K. Applicability of X-Ray computerized tomography in endodontics. *Endod Dent Traumatol* 1990; 6 :16–20.
16. Johal S. Unusual maxillary first molar with 2 palatal canals within a single root: a case report. *J Can Dent Assoc* 2001; 67:211–214.
17. Smadi L, Khraisat A. Detection of a second mesiobuccal canal in the mesiobuccal roots of maxillary first molar teeth. *Oral Surg Oral Med Oral Pathol Oral Radiol Endod* 2007; 103:77–81.
18. Filho FB, Zaitter S, Haragushiku GA, de Campos EA, Abuabara A, Correr GM. Analysis of the internal anatomy of maxillary first molars by using different methods. *J Endod* 2009; 35: 337–342.
19. Chen IP, Karabucak B. Conventional and surgical endodontic retreatment of a maxillary first molar: unusual anatomy. *J Endod* 2006;32: 228–230.
20. Matherne RP, Angelopoulos C, Kulild JC, Tira D. Use of cone-beam computed tomography to identify root canal systems in vitro. *J Endod* 2008;34:87–89.
21. Cleghorn BM, Christie WH, Dong CC. Root and root canal morphology of the human permanent maxillary first molar: a literature review *J Endod* 2006;32:813–821.
22. Holderrieth S, Gernhardt CR. Maxillary molars with morphologic variations of the palatal root canals: a report of four cases. *J Endod* 2009; 35:1060–1065.
23. Patel S, Dawood A, Whaites E. New dimensions in endodontic imaging: part 1. Conventional and alternative radiographic systems. *Int Endod J* 2009; 42 : 447–62.
24. Robinson S, Czerny C, Gahleitner A. Dental CT evaluation of mandibular first premolar root configurations and canal variations. *Oral Surg Oral Med Oral Pathol Oral Radiol Endod* 2002;93:328–32.
25. Farman AG. ALARA still applies. *Oral Surg Oral Med Oral Pathol Oral Radiol Endod* 2005;100:395–7.
26. Scarfe WC. Imaging of maxillofacial trauma: evolutions and emerging revolutions. *Oral Surg Oral Med Oral Pathol Oral Radiol Endod* 2005;100: S 75–96.
27. Mah JK, Danforth RA, Bumann A. Radiation absorbed in maxillofacial imaging with a new dental computed tomography device. *Oral Surg Oral Med Oral Pathol Oral Radiol Endod* 2003; 96: 508–13.
28. Gijbels F, Jacobs R, Bogaerts R. Dosimetry of digital panoramic imaging. Part I: patient exposure. *Dentomaxillofac Radiol* 2005; 34:145–9.
29. Ludlow JB, Davies-Ludlow LE, Brooks SL. Dosimetry of 3 CBCT devices for oral and maxillofacial radiology: CB Mercuray, NewTom 3G and i-CAT. *Dentomaxillofac Radiol* 2006; 35: 219–26.
30. Brooks SL. Effective Dose of Two Cone-Beam CT Scanners: I-CAT and NewTom 3G. Quarterly Publication of the American Association of Dental Maxillofacial Radiographic Technicians. Winter 2005.

Source of Support: Nil, Conflict of Interest: None Declared