

CLINICAL AND RADIOGRAPHIC EVALUATION OF MINERAL TRIOXIDE AGGREGATE PULPOTOMY IN PERMANENT TEETH

Neha Verma¹, Avninder Kaur², Dr Shivesh Acharya³, Dr. Sunila Sharma⁴

¹Post Graduation Student, Pediatric and Preventive Dentistry. Bhojia Dental College and Hospital, Himachal Pradesh, India

²Professor & Head, Pediatric and Preventive Dentistry. Bhojia Dental College and Hospital, Himachal Pradesh, India

³Reader, Pediatric and Preventive Dentistry. Bhojia Dental College and Hospital, Himachal Pradesh, India

⁴Senior Lecturer, Pediatric and Preventive Dentistry. Bhojia Dental College and Hospital, Himachal Pradesh, India

ABSTRACT

Aim and objective: The aim of the present study was to evaluate clinical and radiographic outcome of MTA as a pulpotomy agent in permanent teeth as an alternative to conventional root canal treatment. **Materials and Methods:** Ten permanent teeth with symptoms of irreversible pulpitis with vital pulp were selected for the study. MTA Pulpotomy procedure was done in all the cases using standard protocol. Teeth were evaluated for various clinical and radiographic parameters at 3, 6, 9 and 12 months of follow up. **Results:** None of the patients reported any kind of clinical discomfort or radiographic abnormality during the follow up period of 3, 6, 9 and 12 months. All the teeth responded positive on electric pulp test at all successive follow ups. **Conclusions:** MTA Pulpotomy may be used as an alternative treatment modality to root canal treatment in permanent teeth with irreversible pulpitis, if future research continues to show promising results.

Key words: Growth factors, pulp regeneration, Irreversible pulpitis, MTA Pulpotomy.

INTRODUCTION

The vitality of the dentine-pulp complex is fundamental to the health of the tooth and is a priority for targeting clinical management strategies.¹ The overall response of the tooth to injury, such as dental caries, represents the complex interplay between injury, defence and regenerative processes.² Preservation of vitality of exposed pulp is important in permanent teeth of children to increase the tooth longevity. Pulpal exposures may result from dental caries, iatrogenic mishaps or traumatic injuries.³

Regenerative endodontic procedures involving pulp capping and partial pulpotomy have been in use more than 30 years. Regenerative endodontic procedures can be defined as biologically based procedures designed to predictably replace damaged, diseased, or missing structures, including dentin and root

structures as well as cells of the pulp dentin complex, with live viable tissues, preferably of the same origin, that restore the normal physiologic functions of the pulp dentin complex.^{4,5}

Pulpotomy is a vital pulp therapy in which a portion of coronal pulp tissue is removed surgically, and the remaining radicular tissue is covered with a suitable material that protects the pulp from further injury and promotes healing.^{6,7} In primary teeth, pulpotomy is a preferred procedure as several case studies have suggested pulpotomy as a viable treatment for pulp exposures with pulpitis; the rationale being the healing potential of the remaining radicular tissue and the biocompatibility of pulpotomy agents.⁸

However, the cells from diseased pulp demonstrate decreased colony formation capacity and slightly decreased

Corresponding Author:
Manjit Kumar
E-mail:

neha4334@hotmail.com

Received: 12th September 2016

Accepted: 2nd December 2016

Online: 20th January 2017

cell proliferation rate, but they had similar STRO-1 expression and exhibits a similar percentage of positive *ex vivo* osteogenic induction and dentin sialophosphoprotein expression from STRO-1 enriched pulp cells and makes regenerative procedures possible in irreversible pulpitis.⁹ Therefore, biocompatible treatments directed at maintaining pulp vitality and increasing tooth longevity would rather be preferred procedure or more suitable for maintaining the vitality of teeth.²

Numerous *in vivo* and *in vitro* studies have reported excellent physiochemical and biological properties of MTA, i.e. good sealing ability, hydroxyapatite formation and favourable biocompatibility.¹⁰⁻¹¹ Recent research has shown that MTA, when placed in direct contact with the human dental pulp cells, differentiated them into odontoblast-like cells.¹² Therefore, the aim of this study was to evaluate the effectiveness of MTA as pulpotomy agent in permanent teeth with irreversible pulpitis.

MATERIALS AND METHODS

The present study was carried out in the Outpatient Department of Pediatric and Preventive Dentistry, Bhojia Dental College and Hospital, Bhud, Baddi. A total 10 teeth (8 molars, 2 incisors) from the patients in the age range of 10-16 years were selected for the study. The study was approved by Institutional Ethical Committee of Bhojia Dental College and Hospital, Bhud, Baddi. The teeth with history of spontaneous nocturnal pain, clinically active caries invading the pulp, incisors with Ellis class III fracture were selected for the study. All the 10 teeth were checked for vitality before inclusion in the study and all responded positive. The teeth with necrosed pulp or fistula/periapical abscess, internal & external resorption, abnormal mobility periapical radiolucencies were excluded from the study. After deforming the standard clinical procedure of MTA Pulpotomy all treated teeth were evaluated for various clinical and radiographical parameters viz pain, swelling, mobility, abscess, sinus tract, discoloration, periapical radiolucency, thickening of lamina dura and tooth discoloration at 3,6 and 9 and 12 months.

Clinical Procedure:

After recording thorough medical and dental history and performing required investigations, informed written consent explaining nature of the study was obtained from the parents of the selected children. All the clinical and radiographic parameters were recorded on a specially designed proforma. The tooth vitality was checked with the electric pulp tester. After administration of local anaesthesia, the tooth was isolated with rubber dam. The crown of tooth and surrounding rubber dam was disinfected by applying hydrogen peroxide (30%) for 30 seconds followed by tincture iodine (5%) for one minute and the disinfectant was inactivated by Sodium thiosulphate solution (5%) for one minute. Access cavity was prepared with a round bur using high speed air rotor handpiece with continuous irrigation using normal saline, and coronal pulp tissue was removed to the level of pulp chamber floor with a sharp spoon excavator. Hemostasis was achieved by irrigating the cavity with sterile saline and use of wet cotton pellets which was placed over exposed pulp stumps for 10-15 minutes. The pulp tissue thus removed was transported in formalin to the Oral Pathology Laboratory for histopathological examination (Figure 1). After achieving haemostasis, the blood clot free pulpal wound was directly covered with approximately 2-mm thick layer of MTA. A sterile cotton pellet moistened with distilled water was placed over MTA and patient was asked to wait for 15- 20 minutes. Then, the final restoration with RMGIC was done. The clinical and radiographical parameters were evaluated for all the teeth at 3,6 and 9 and 12 months. The pain was evaluated by using the visual analog scale (VAS) that is a measurement instrument which tries to measure a characteristic or attitude that is believed to range across a continuum of values and cannot easily be directly measured. Data were compiled and Chi-square test was applied.

RESULTS

Evaluation of clinical parameters is shown in table 1 and revealed, no pathology on successive follow ups except for discoloration. After 24 hours of evaluation all the patients complained of mild pain and

Table1. Evaluation of the parameters at baseline and follow up examination

Clinical Parameters	Follow up				
	Baseline	3 months	6 months	9 months	12 months
Pain as per VAS	7	0	0	0	0
Swelling	2*	2	2	2	2
Tenderness on Percussion	2	1*	2	2	2
Mobility	2	2	2	2	2
Discoloration	2	2	1	1	1
Sinus tract	2	2	2	2	2
Abscess	2	2	2	2	2

Where* 1 = Yes and 2 = No

tenderness on percussion, but after 3, 6, 9 and 12 months of follow up, there was complete absence of pain.

Radiographic evaluation is shown in table 2, the teeth were assessed for internal and external resorption, periapical radiolucency, and thickening of lamina dura. No abnormal radiographical features were

Table 2: Evaluation of the radiographic parameters at baseline and follow up examination

Radiological Parameters	Follow up				
	Baseline	3 months	6 months	9 months	12 months
Internal Resorption	2*	2	2	2	2
External Resorption	2	2	2	2	2
Periapical Radiolucency	2	2	2	2	2
Thickening of lamina Dura	2	2	2	2	2

*1= Yes and 2- No

noted after 3, 6, 9 and 12 months (Figure 1-5).

The table 3 shows the observations of EPT value that were recorded at baseline and follow up. Histopathological examination of the pulp tissue

Table 3. EPT values at baseline and follow up

VALUES	N	Mean±Std. Deviation	p- value
Control value*	10	12.2±1.69	0.2456**
Baseline value	10	10.2±0.74	
3 months	10	11.2±1.57	0.2258***
6 months	10	12.1±1.73	0.9472****
9 months	10	13.2±1.62	0.7548*****
12 months	10	12.4±1.58	0.5524*****

*- contralateral healthy tooth, **-control vs baseline, ***- Baseline vss 3 months, **** Baseline vs 6 months, ***** Baseline vs 9 months and, ***** Baseline vs 12 months

removed showed chronic inflammatory cells.

DISCUSSION

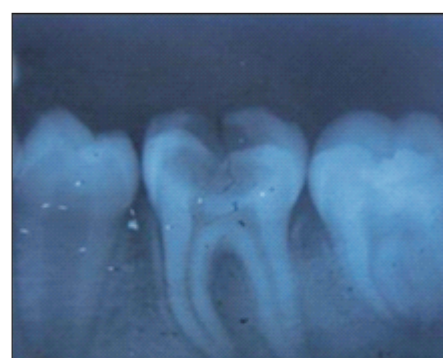

Figure 1: Pre-Operative IOPA radiograph

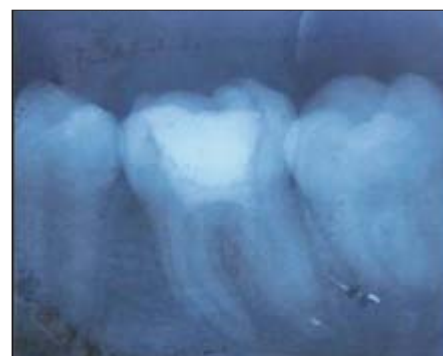

Figure 2: Follow up at 3 months after MTA pulpotomy

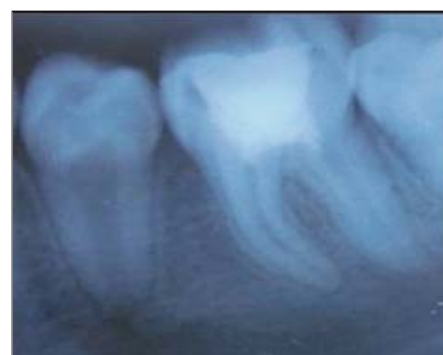

Figure 3: Follow up at 6 months after MTA pulpotomy

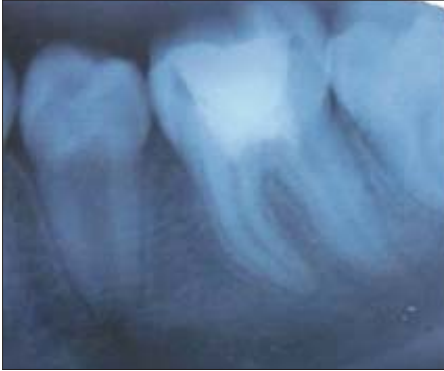

Figure 4: Follow up at 9 months after MTA pulpotomy

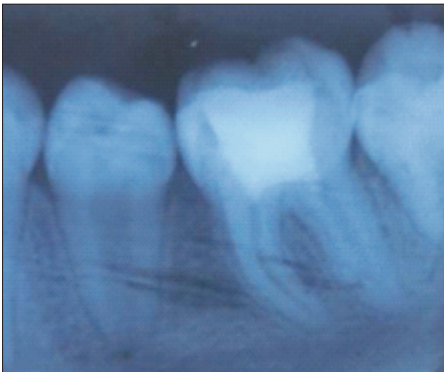


Figure 5: Follow up at 12 months after MTA pulpotomy

Endodontology has shifted towards postponing or avoiding non-biological treatment and descending down the restorative spiral, which would significantly reduce the long-term prognosis for tooth retention and function.¹³ Recent studies have suggested vital pulp therapy (VPT) as a realistic treatment modality for pulp exposures with supposed irreversible pulpitis.¹⁴⁻¹⁶ Vital pulp aims to preserve and maintain pulp tissue that has been compromised but not destroyed by caries, trauma, or restorative procedures in a healthy state. On the other hand VPT for mature permanent teeth with irreversible pulpitis and/or carious pulp exposure remains one of the most challenging/controversial areas in dentistry.¹⁷

Various authors used MTA as a pulp dressing for partially pulpotomised permanent molars in a preliminary study and reported a 100% success rate over 12-26 months.¹⁸ Like Calcium hydroxide, MTA also has an alkaline pH (12.5) which not only causes denaturation and necrosis of the adjacent pulp but

which also confers bactericidal activity. In addition, MTA has been shown to produce less inflammation and higher quality bridge formation and also it possesses osteoinductive property when compared to Calcium hydroxide.¹⁹ Clinicians report favourable treatment outcomes and various research reports indicate that this material is biocompatible, encourages pulp, bone and periodontal ligament repair, and it seals well in the presence of fluid.²⁰ White MTA (Angelus) which has less Calcium sulphate, was used in the present study because it has very short setting time of 15 min as compared to Proroot MTA which sets about 2.5-4 hours.¹²

In this study, the age group was taken in the range of 10-16 years as there is evidence regarding the effect of the patient's age and the status of the root apex on the outcome of vital pulp therapy. According to Malekafzali B et al (2011)²¹ it had been suggested that aged pulp retains the ability to create dentine but at a diminished rate. They also concluded that younger pulps had a better likelihood of potential tissue healing and regeneration. An explanation for this could be provided from a recent review on dental pulp stem cells where it had been demonstrated that ageing was related to reduction of pulpal cell populations leading to compromised pulpal wound healing and regeneration with increasing age.²²

The clinical success is measured when there is absence of spontaneous or nocturnal pain, excessive mobility, tenderness on percussion, abscess, swelling or fistula according to previous studies. None of the pulpotomy cases in the present study showed any above mentioned pathological signs and symptoms at follow up examination at 3, 6, 9 and 12 months post operatively. Pain which was present at baseline disappeared at successive follow up visits which might be related to decrease in pulpal inflammation secondary to pulpal regeneration of stem cells present in pulp following pulpotomy procedure. Eghbal et al.²³ studied the short term clinical and histological outcomes of MTA pulpotomy of 12 permanent molars with irreversible pulpitis. Clinically, no complaint of discomfort or tenderness on percussion in the next day was reported. Witherspoon et al³ also revealed good clinical and

radiographic outcomes of MTA pulpotomy for 19 symptomatic permanent teeth in 14 patients at the follow up of 19.7 months. Dominguez et al²⁴ following histological evaluation of radicular pulp reported that MTA caused minimal pulpal inflammation. Recent reviews and meta-analysis done by various authors also reported high success rates of Pulpotomy in primary teeth with MTA. In contrast Anthonappa et al²⁵ reported no evidence that MTA was better than present materials and techniques as pulpotomy medicament.

In the present study, the EPT values were recorded at baseline for each tooth in which the mean was 10.2 ± 0.74 before the start of treatment (Table 3). There was no statistically significant difference found between this value and value obtained from control healthy tooth. The pulp responded positively to electric pulp test in all the cases before the treatment and at the follow up examination visits. Results showed no statistically significant difference between the baseline values i.e. preoperatively and the values obtained at follow up visits of 3, 6, 9 and 12 months.

In this study, radiographic parameters i.e. internal and external resorption, periapical radiolucency and thickening of lamina dura that were recorded at 3, 6, 9 and 12 months revealed no abnormal radiographic change.

The present study had few limitations. The clinically significant discoloration was observed in all cases which limit its use in esthetic zone. Histological evaluation was not possible to confirm the hard tissue bridge formation. Larger sample size with longer follow up is required to see the long term success of MTA pulpotomy.

CONCLUSION

Considering the results obtained in the present study, it can be concluded that the MTA can be used as pulpotomy agents as an alternative to root canal treatment in permanent teeth with irreversible pulpitis. Further clinical trials and research is necessary to compare the effects of MTA alone and in combination with other agents in pulp repair or regeneration of irreversibly damaged radicular pulp on a larger sample size and longer follow up time period. Histological

success could not be confirmed which needs extraction of treated tooth, which was not possible in present study.

REFERENCES

1. Smith AJ. Vitality of the dentin-pulp complex in health and disease: growth factors as key mediators. *J Dental Educ* 2003; 67: 678–89.
2. Hiremath H, Saikalyan S, Kulkarni SS & Hiremath V. Second-generation platelet concentrate (PRF) as a pulpotomy medicament in a permanent molar with pulpitis: a case report. *Int Endod J* 2012; 45: 105–12.
3. Witherspoon DE, Small CJ, Harris ZG. Mineral trioxide aggregate pulpotomies. A case series outcomes assessment. *J Am Dent Assoc* 2006; 137: 232-5.
4. Godyl FG, Murray PE. Recommendations for using regenerative endodontic procedures in permanent immature traumatized teeth: invited review. *Dent Traumatol* 2012; 28: 33-41.
5. Murray PE, Garcia-Godoy F, Hargreaves KM. Regenerative endodontics. A review of current status and call for action. *J Endod* 2007; 33: 377-90.
6. Bakland LK. Endodontic consideration in dental trauma. In: Ingle JI, Bakland LK, eds. *Endodontics*. Toronto: BC Decker Inc: 2002:795-844.
7. Fuks AB. Current concepts in vital primary pulp therapy. *Eur J Paediatr Dent* 2002;3:115-20.
8. Asgary S, Eghbal MJ. A clinical trial of pulpotomy vs. root canal therapy of mature molars. *J Dent Res* 2010;89:1080–5.
9. Wang Z, Pan J, Wright JT. Putative stem cells in human dental pulp with irreversible pulpitis: An Exploratory Study. *J Endod* 2010; 36: 820-5.
10. Hu CC, Zhang C, Qian Q, Tatum NB. Reparative dentin formation in rat molars after direct pulp capping with growth factors. *J Endod* 1998;24: 744–51.
11. Sloan AJ, Smith AJ. Stimulation of the dentine-pulp complex of rat incisor teeth by transforming growth factor beta isoforms 1-3 in vitro. *Arch Oral Biol* 1999; 44: 149–56.
12. Dentsply Endodontics. Materials safety data sheet (MSDS): ProRoot MTA (mineral trioxide aggregate) root canal repair material. Effective March 1, 2001.
13. Caplan DJ, Cai J, Yin G, White BA. Root canal filled versus non-root canal filled teeth: a retrospective comparison of survival times. *J Public Health Dent* 2005;65: 90–6.
14. McDougal RA, Delano EO, Caplan D, Sigurdsson A, Trope M.

- Success of an alternative for interim management of irreversible pulpitis. *J Am Dent Assoc* 2004; 135:1707–12.
15. Eghbal MJ, Asgary S, Baglue RA, Parirokh M, Ghoddusi J. MTA pulpotomy of human permanent molars with irreversible pulpitis. *Aust Endod J* 2009; 35:4–8.
 16. Asgary S, Ehsani S. Permanent molar pulpotomy with a new endodontic cement: a case series. *J Conserv Dent* 2009; 12:31–6.
 17. Chacko V, Kurikose S. Human pulpal response to mineral trioxide aggregate (MTA): A histologic study. *J Clin Pediatr Dent* 2006;30: 203–9.
 18. Aeinehchi M, Eslami B, Ghanbariha M, Saffar AS. Mineral trioxide aggregate (MTA) and calcium hydroxide as pulp-capping agents in human teeth: a preliminary report. *Int Endod J* 2002; 36: 225-31.
 19. Barnkggei IH, Halboub ES, Alboni RS. Pulpotomy of Symptomatic Permanent Teeth with Carious Exposure using Mineral Trioxide Aggerate. *Iran Endod J* 2013; 8(2):65-8.
 20. Schwarz R, Mauger M, Clement D, Walker W. Mineral trioxide aggregate: a new material for endodontics. *J Am Dent Assoc* 1999;130: 967-75.
 21. Malekafzali B, Shekarchi F, Asgary S. Treatment outcomes of pulpotomy in primary molars using two endodontic biomaterials. A 2-year randomised clinical trial. *Eur J Paediatr Dent* 2011;12:189–93.
 22. Aguilar P, Linsuwanont P. Vital pulp therapy in vital permanent teeth with cariously exposed pulp: a systematic review. *J Endod* 2011; 37:581–7.
 23. Eghbal MJ, Asgary S, Baglue RA, Parirokh M, Ghoddusi J. MTA pulpotomy of human permanent molars with irreversible pulpitis. *Aust Endod J* 2009; 35:4–8.
 24. Dominguez RA, Munoz ML, Aznar MT. Study of calcium hydroxide apexification in 26 young permanent incisors. *Dent Traumat* 2005; 21:14-5.
 25. Anthonappa RP, King NM, Martens LC. Is there sufficient evidence to support the long term efficacy of mineral trioxide aggregate (MTA) for endodontic therapy in primary teeth? *Int Endod J* 2013; 46: 198-204.

Source of Support: Nil, Conflict of Interest: None Declared