

## THE UNPARALLELED BENIGN ODONTOGENIC TUMOR : PERIPHERAL ODONTOGENIC FIBROMA-A CASE REPORT

Puneet Bajaj, Deepti Garg , Robin Sabharwal , Sonia Joshi , Ruchi Sharma<sup>1</sup>

<sup>1</sup>Prof. & Head Department of Oral and Maxillofacial Pathology, Bhojia Dental College & Hospital, Himachal Pradesh, India

<sup>2</sup>Reader Department of Oral and Maxillofacial Pathology, Bhojia Dental College & Hospital, Himachal Pradesh, India

<sup>3</sup>Senior Lecturer, Department of Oral and Maxillofacial Pathology, Bhojia Dental College & Hospital, Himachal Pradesh, India

<sup>4</sup>Senior Lecturer, Department of Oral and Maxillofacial Pathology, Bhojia Dental College & Hospital, Himachal Pradesh, India

<sup>5</sup>Post Graduate Student Department of Oral and Maxillofacial Pathology, Bhojia Dental College & Hospital, Himachal Pradesh, India

### ABSTRACT

Peripheral odontogenic fibroma (POF) is a rare odontogenic tumor. It resembles clinically with other peripheral exophytic lesions like pyogenic granuloma, peripheral ossifying fibroma, and peripheral giant cell granuloma. Hence, needs to be differentiated from such other lesions. Histopathological examination being the only diagnostic approach for peripheral odontogenic fibroma, which can provide a basis for treatment and prognosis evaluation. This case report presents a rare clinical case of a 14-year-old female patient with a palatal overgrowth along the maxillary incisors, which was diagnosed as peripheral odontogenic fibroma.

**Keywords:** Exophytic mass, Inflammatory Hyperplasia, Odontogenic tumor, Peripheral Odontogenic Fibroma, WHO variant.

### INTRODUCTION

POF is an uncommon, benign, exophytic gingival mass of fibrous connective tissue covered with surface epithelium and containing odontogenic epithelium within the connective tissue. It can occur as two variants peripheral and central. POF is further classified into simple and WHO (World Health Organization) variant. POF (WHO) variant, is defined by WHO as a fibroblastic neoplasm containing varying amounts of apparently inactive odontogenic epithelium. It may contain dentin and/or material resembling cementum.<sup>1</sup> POF presents a slow-growing, progressive but painless swelling, often associated with cortical expansion or tooth displacement. There is a slight female predominance in literature.<sup>2</sup> Here, in the present article we

report an uncommon case of POF in a young female child and hereby discuss the clinical, differential diagnosis, of the rare lesion.

### CASE REPORT

A 14-year-old female reported to the Department of Oral Pathology and Microbiology of Bhojia Dental College & Hospital, Baddi, with the chief complaint of swelling in anterior palatal region of jaw since 2 years. The patient had no history of pain, trauma, and infection. Family history and medical history were non contributory. Patient was physically healthy with no significant extraoral findings. On intraoral examination, a pale pink, sessile, smooth, firm, non-inflammatory, well-defined growth was present on the palatal area between maxillary right central incisor and lateral incisor, measuring approximately 1.5 × 1.0 cm.

#### Corresponding Author:

Manjit Kumar

E-mail:

dr.ruchikatoch@gmail.com

Received: 2<sup>nd</sup> August 2016

Accepted: 30<sup>th</sup> November 2016

Online: 20<sup>th</sup> January 2017

(Figure 1).The patient reported that she noticed the swelling 2 years back, which was of a small lemon seed size and gradually increased to the present size. The patient reported of no symptoms like pain or mobility of the upper incisor. Radiographic examination revealed no bone loss in the same region . Based on clinical and radiographic findings, a provisional diagnosis of a pyogenic granuloma was made. Differential diagnosis included peripheral exophytic lesions such as irritational fibroma, peripheral ossifying fibroma, peripheral giant cell granuloma, peripheral odontogenic fibroma .

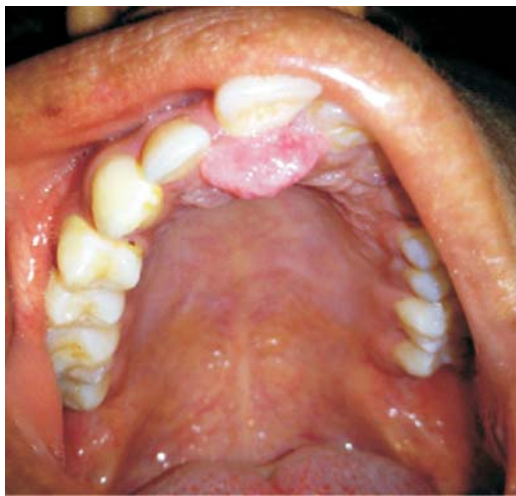

Figure 1 : Intraoral view showing smooth sessile swelling in anterior palatal region

A laser cauterization of the lesion was performed under local anaesthesia. The soft tissue was sent to the department of Oral Pathology for histopathological evaluation. Microscopic evaluation of the tissue revealed parakeratinized stratified squamous epithelium with elongated and slender rete ridges and the underlying connective tissue showing collagen fibers with dense and focal infiltration of chronic inflammatory cells predominantly being lymphocytes. Numerous inactive odontogenic epithelial islands in the form of islands and cords, along with numerous calcified areas were also seen within the connective tissue. Based on these histopathological findings, final diagnosis of Peripheral Odontogenic Fibroma (WHO variant) of gingiva due to presence of inactive odontogenic epithelial islands and foci of calcifications was made (Fig 2, Fig 3, Fig 4 )

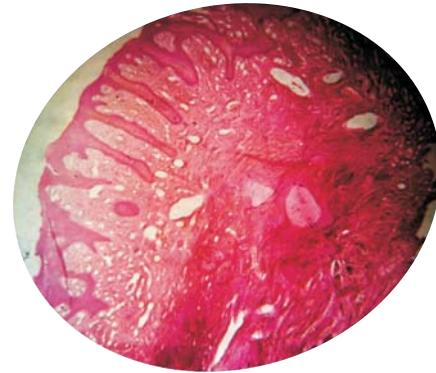


Figure 2: Photomicrograph of the lesion under microscope, scanner view (4x) showing parakeratinized stratified squamous epithelium, elongated and slender rete ridges, and underlying connective tissue.

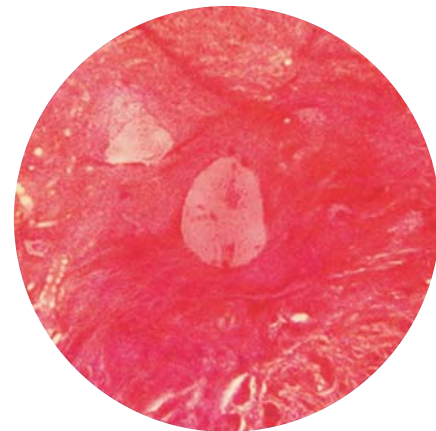


Figure 3

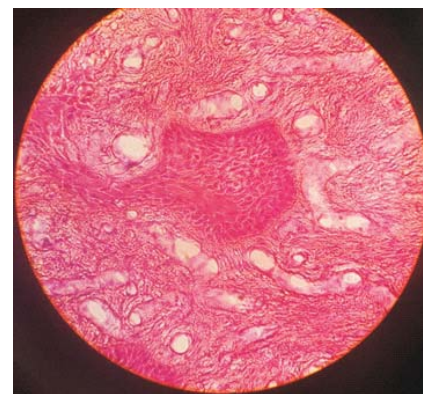

Figure 4: High-power (40 x) Photomicrographic view showing calcification depicted by white arrow (Figure 3 ) along with scattered islands of odontogenic epithelium (black arrow)

## DISCUSSION

Peripheral odontogenic fibroma is the rare peripheral counterpart of central odontogenic fibroma. The lesion

can occur in age group ranging from 11- 66 years ,with mean age of 39.8 years.<sup>3</sup> There is slight female predominance, and there is predilection for the occurrence of it in the mandible in comparison to the maxilla.<sup>2,4</sup> Clinically, it presents as an uncommon, benign, unencapsulated exophytic mass, which may be sessile or pedunculated, red or pink, usually with smooth surface, and in some ,mucosa may be ulcerated. On palpation, the lesion is usually firm and non-tender .<sup>1</sup> It is an apparently innocuous, elevated gingival lesion that has no conclusive data regarding its exact prognosis. It is generally believed that peripheral odontogenic fibroma originates from mesenchymal tissue.<sup>5</sup> POF comprises approximately 1.2% of all odontogenic cysts and tumors.<sup>6</sup>

In our case the lesion occurred in a young female of 14 years which itself is rare to occur, since few cases have been reported . In past reviews PODFs in children aged 0-19 years revealed that 35 of cases of all ages ( $n=151,23.2\%$ ) involved children, the youngest of which was five years old. Another case series described 6 of all 23 patients (26%) being between 12-18 years of age.<sup>7</sup> Daley and Wysocki's survey revealed that 6 of 36 new cases of all ages were within 0-19 years of age the youngest being 12 years old.<sup>8</sup> The lesion occurred in the maxilla in our case ,while the predilection is for the mandible which also reflects the rarity in our case. As, according to Shafer et al, only four cases in the maxilla have been reported .<sup>4</sup>

The present lesion needs to be diagnosed and differentiated from other lesions, as described in brief below.

POF may be confused histologically with peripheral types of ameloblastoma because of epithelial proliferation but epithelial islands of the POF are smaller than those of ameloblastoma and do not exhibit hyperchromatism, intracytoplasmic vacuoles, and polarization of the nucleus away from the basement membrane in basal cell layer. Also, hard tissues, such as dentin or cementum, are not found in ameloblastoma, although they are not present in all examples of POF.<sup>9</sup>

Peripheral ossifying fibroma is a benign reactive gingival lesion arising from the periodontal ligament,

which was confused with odontogenic fibroma , it was later that WHO designated the term peripheral odontogenic fibroma for the condition quite different from peripheral ossifying fibroma . The peripheral ossifying fibroma is commonly seen in teenagers and young adults with a peak incidence in the second decade, and is common in the incisor-cuspid region. Clinically, the lesions presents as sessile or pedunculated nodules with a smooth to cauliflower-like surface that ranges from pink to red in color. These are mostly firm, non-tender enlargements, developing within the interdental papillae. In peripheral ossifying fibroma, fibroblastic proliferation admixed with mineralization foci are commonly observed, presenting a cementum-like, bony, or dystrophic calcification.<sup>11</sup>

Another lesion, to be differentiated is the peripheral giant cell granuloma It is clinically present as polypoid or nodular lesions located on the gingiva or edentulous alveolar ridge. It is common in older females, and is predominantly found in mandibular premolar and molar regions. On palpation, the lesion is rubbery to soft. There may be a cupping type of resorption in the underlying bone.<sup>10</sup>

Hence , the purpose of this article is to report a case of this uncommon lesion which occurred in a 14 year old female in the anterior part of the maxilla. The lesion was removed by laser cauterization and the follow up of the patient was done to ascertain its relapse. As, according to Daley and Wysocki there was significant recurrence rate (38.9%) while Ritwik et al reported recurrence rate of 50%. The reason cited for recurrence was budding of basal cell layer of surface epithelium.<sup>12</sup>

## CONCLUSION

The present case report of localized gingival enlargement is unique in terms of its age of occurrence, but findings such as odontogenic epithelial island within the fibrous connective tissue and calcifications during histopathologic examination leads us to definitive diagnosis of peripheral odontogenic fibroma. Thus localized gingival enlargement should be carefully evaluated so that accurate diagnosis can be made for the benefit of the patient.

## REFERENCES

1. Nikam SS, Gadgil RM, Bhoosreddy AR, Shah KR. Peripheral odontogenic fibroma: A case report and review of literature. *J Indian Acad Oral Med Radiol* 2015;27:140-2.
2. Jing Q, Feng L, Zuyan Z. Peripheral Odontogenic Fibroma: A Case Report and Review of The Literature. *Adv Dent & Oral Health*.2016; 2 (1):1-3
3. Peter A Reichart , Philipsen P. Hans. Text book of Odontogenic tumors And allied lesions,2004 Edition.
4. Shafer, Hine, Levy. Text book of oral pathology. Seventh edition.
5. Pippi R, Santoro M, Patini R . The central odontogenic fibroma: How difficult can be making a preliminary diagnosis. *J Clin Exp Dent* 2016; 8(2):1- 5 .
6. Siar CH, Ng KH. Clinicopathology study of peripheral odontogenic fibromas (WHO-type) in Malaysians (1967-95).*Br J Oral Maxillo fac Surg* 2000; 38:19- 22 .
7. Buchner A, Merrell PW, Carpenter WM. Relative frequency of peripheral odontogenic tumors: a study of 45 new cases and comparison with studies from the literature. *J Oral Pathol Med* 2006 ; 35:385-391 .
8. Daley TD, Wysocki GP. Peripheral odontogenic fibroma. *Oral Surg Oral Med Oral Pathol* .1994;78: 329-336 .
9. Gardner DG. The peripheral odontogenic fibroma: An attempt at clarification. *Oral Surg Oral Med Oral Pathol* 1982; 54:40-8.
10. Zalzal GH, Patterson K, Cotton RT. Congenital tumors of the dorsum of the tongue. *Int J Pediatr Otorhino laryngol* 1994 ; 28 :219-2.
11. Adebayo ET, Ajike SO, Adekeye EO. A review of 318 odontogenic tumors in Kaduna, Nigeria. *J Oral Maxillofac Surg* 2005; 63(6): 811- 819 .

**Source of Support: Nil, Conflict of Interest: None Declared**