

# Revisiting King Appliance Space Regainer in Children: A Case Report with 1-Year Follow-Up

Aman Deep<sup>1</sup> Dipti Chawla<sup>2</sup>

<sup>1</sup>Department of Pediatric and Preventive Dentistry, Bhojia Dental College and Hospital, Baddi, Solan, Himachal Pradesh, India

<sup>2</sup>Department of Orthodontics and Dentofacial Orthopedics, Bhojia Dental College and Hospital, Baddi, Solan, Himachal Pradesh, India

Address for correspondence Dipti Chawla, MDS, Department of Orthodontics and Dentofacial Orthopedics, Bhojia Dental College and Hospital Baddi, Solan, Himachal Pradesh 173205, India (e-mail: diptichawla36@gmail.com).

Dent J Adv Stud 2021;9:161–165.

## Abstract

### Keywords

- ▶ Interceptive Orthodontics
- ▶ Tooth movement techniques
- ▶ Nickel-Titanium Alloys

In recent times, for successful resolution of space discrepancies, a plethora of interceptive measures involving nonextraction approaches have been employed judiciously. Immaculate diagnosis and treatment planning help to prevent failure in diagnosing a case of space discrepancy and space regaining. This article describes a case in which space loss in the posterior quadrant of mandibular arch was successfully regained by employing King Appliance space regainer in an adolescent male, following which successful eruption of unerupted tooth took place. Additionally, after 1 year of follow-up, no marked reduction in arch dimension was seen.

## Introduction

Interceptive orthodontics employed during developing dentition helps to promote favorable developmental changes.<sup>1</sup> It is defined as a phase of science and art of orthodontics employed to recognize and eliminate the potential irregularities and malpositions in the developing dentofacial complex.<sup>2</sup> Kisling and Hoffding<sup>3</sup> reported that premature loss of the primary tooth led to space loss, which could manifest in either impaction of the succedaneous tooth or ectopic eruption of the tooth; hence, “preservation of the primary tooth as a natural space” remains a statement of great magnitude during transitional dentition. However, lost spaces due to premature shedding can be regained by employing various space regainer appliances.<sup>4</sup>

Of these numerous space regainers discussed in literature, NiTi Open coil space regainer has been effectively used for space regaining. This concept of using NiTi Coil springs for unravelling of teeth was suggested in the year 1975.<sup>5</sup> A NiTi Open coil spring is made of alloy wire which exhibits shape

memory, thus allowing excellent superelastic and spring back properties. The open coil spring produces light continuous forces through a long range of activation, with production of forces in the range of 100 to 150 g.<sup>6</sup> This NiTi Open coil spring is an intrinsic part of functioning of King Appliance space regainer and its mechanism to gain space in molar region in both arches. Here is a representation of a case with space loss and blocked out erupting second premolar where King Appliance space regainer was effectively used for space regaining.

## Case Report

An 11-year-old male patient reported to the Department of Pediatric and Preventive Dentistry, with the chief complaint of irregular front teeth since 2 years. There was noncontributory medical history, while past dental history showed that patient was receiving treatment using fixed mechanotherapy in maxillary arch and space maintenance in mandibular arch from a dental institution where he was previously residing. The previous dental records depicted patient had

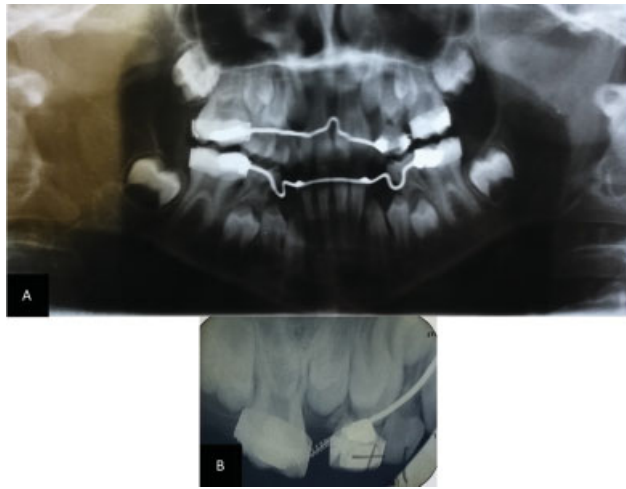
published online  
October 18, 2021

DOI <https://doi.org/10.1055/s-0041-1736265>.  
ISSN 2321-1482.

© 2021. Bhojia Dental College and Hospital affiliated to Himachal Pradesh University. All rights reserved.

This is an open access article published by Thieme under the terms of the Creative Commons Attribution-NonDerivative-NonCommercial-License, permitting copying and reproduction so long as the original work is given appropriate credit. Contents may not be used for commercial purposes, or adapted, remixed, transformed or built upon. (<https://creativecommons.org/licenses/by-nc-nd/4.0/>)

Thieme Medical and Scientific Publishers Pvt. Ltd., A-12, 2nd Floor, Sector 2, Noida-201301 UP, India



**Fig. 1** (A) Orthopantomogram from previous records showing orthodontic appliances. (B) Intraoral periapical (IOPA) radiograph showing open coil space regainer in maxillary posterior quadrant.

undergone space regaining in maxillary arch and lingual arch space maintenance in mandibular arch (►Fig. 1A, B). On examination, patient had a mixed dentition with a total of 22 teeth present. The details of dentition are given in ►Table 1. Pit and fissure carious lesions were present in 75 and 85. Additionally, patient had a bonded maxillary arch with 0.016-inch NiTi wire and NiTi open coil spring placed between tooth 14 and 16, while a bonded lingual arch was placed in mandibular arch (►Fig. 2A–C). Patient had an Angle's class I molar relation on left side and Angle's class III molar relation on right side, due to space loss in mandibular arch. Patient had an increased overjet of 5 mm and

**Table 1** Mixed dentition

Teeth present: 16,55,14,13,12,11,21,22,23,24,25,26
46,85,43,42,41,31,32,33,75,36

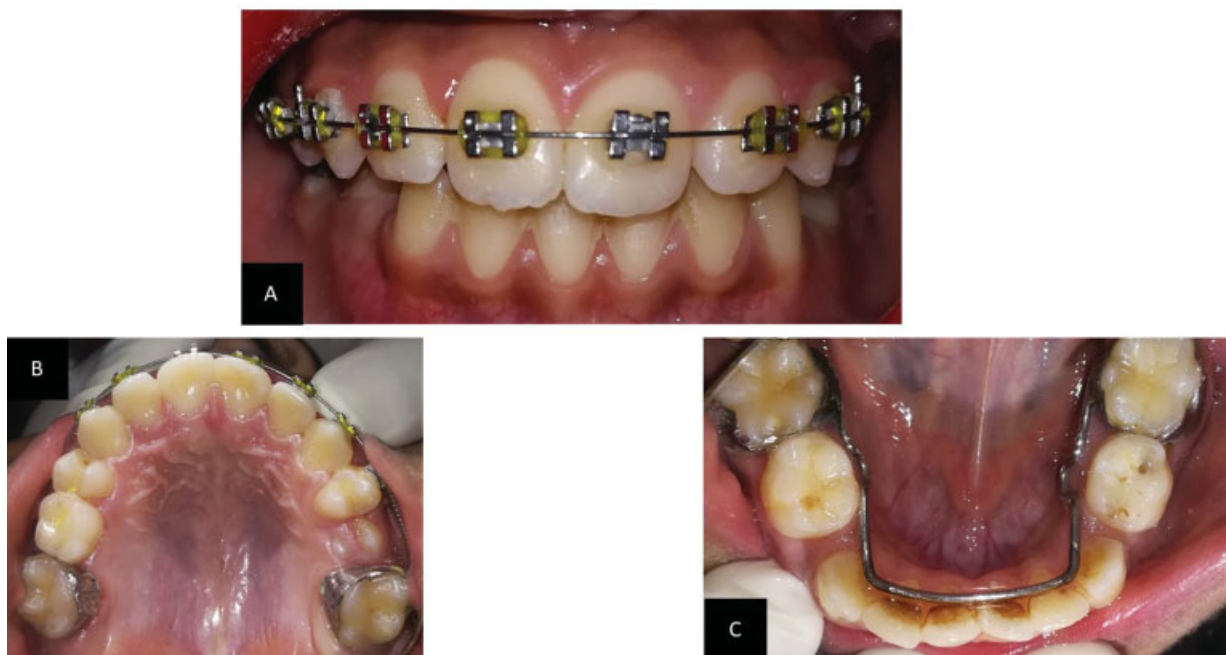dental midline shifted toward left side by 4 mm. Overall oral hygiene of the patient was poor with generalized stains and calculus present.

### Treatment Objective

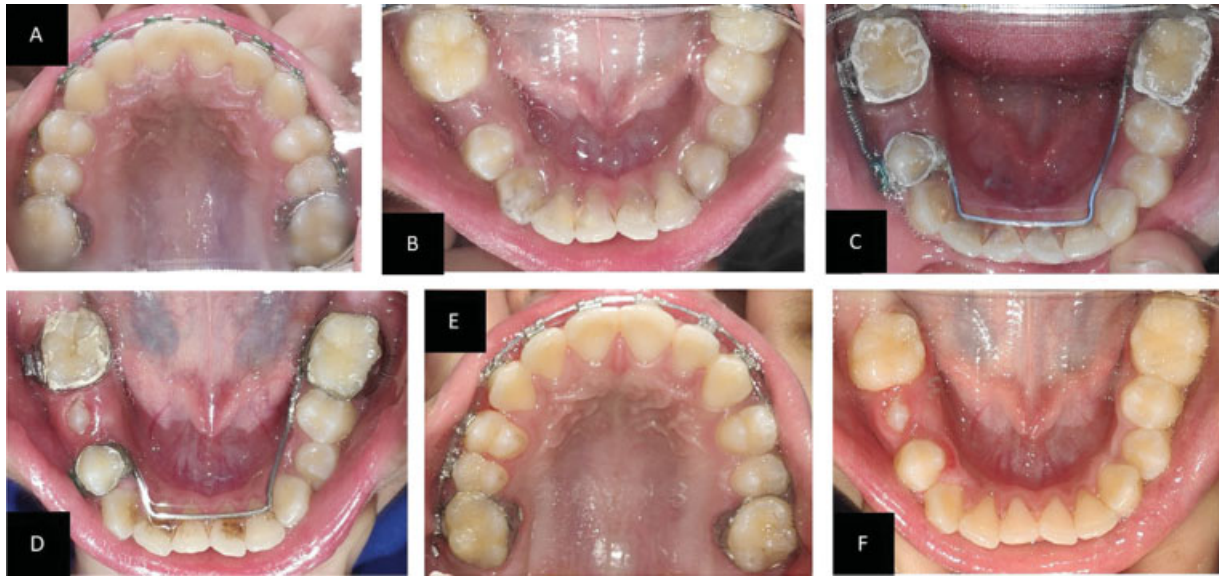The treatment objective was to resolve the crowding, obtain an Angle's class I canine and molar relationship with a normal overbite and overjet, and improve the facial profile.

### Treatment Progress

The stage at which the patient presented to us, the space had already been regained, and emergence of maxillary right second premolar was seen, while in mandibular arch, bonded lingual arch was present, and it was planned to continue the treatment as such while we waited for physiologic shedding followed by eruption of premolar. Over the period of one and half year, patient again presented to us with erupted maxillary second premolars, which we included into the fixed mechanotherapy, and erupted mandibular first premolars and left second premolar, while inadequate space was seen to be present for right mandibular second premolar (►Fig. 3A, B). An intraoral periapical radiograph was taken which showed the premolar to be in Nolla's stage 8 of formation (►Fig. 4A). The mesiodistal space available, as



**Fig. 2** (A) Intraoral frontal view showing midline shift toward left side. (B) Maxillary occlusal view shows emergence of left second premolar. (C) Mandibular occlusal view shows marked space loss for succedaneous teeth and staining of teeth.



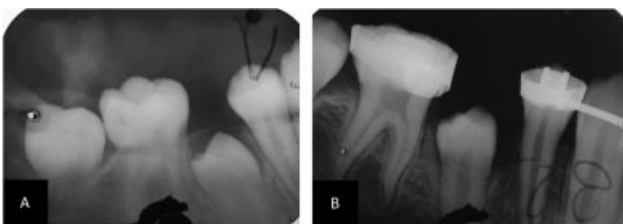**Fig. 3** (A) Maxillary occlusal view shows erupted permanent dentition undergoing fixed mechanotherapy. (B) Mandibular occlusal view shows erupted 1st premolars and space deficiency for right second premolar. (C) Cementation of King Appliance with activated NiTi open coil spring. (D) Space regained and eruption of right second premolar. (E) Closing of spaces in maxillary arch. (F) Debonded mandibular occlusal view.

seen by Vernier caliper on right side of mandibular arch, was found to be 4 mm deficient for eruption of tooth, as the dimension of second premolar on left side of the dental cast was found to be 8 mm mesiodistally. It was decided to gain space on the right side of the arch, using King Appliance space regainer. A modified lingual arch was built, extending from left mandibular first permanent molar to right mandibular first premolar, and was soldered to stainless steel bands of  $0.004'' \times 0.150''$  and  $0.005'' \times 0.180''$ , respectively. Another molar band was constructed for right mandibular first molar, using the above band specification itself. An edgewise bracket of  $0.022'' \times 0.028''$  slot size was spot welded on band of right mandibular premolar band, while a buccal tube of 0.7-mm diameter and 10-mm length was spot welded to the band of right mandibular first molar. The bands and the modified lingual arch are then cemented over the teeth, using luting glass ionomer cement. Once the bands were cemented, a NiTi open coil spring (Rabbit Force USA;  $012'' \times 030''$ ) was threaded with a 0.018-inch stainless steel wire of length, suitable to span the distance between the right-side mandibular molar and first premolar. The length of open coil was 2 mm greater than the distance between the molar tube and bracket welded over the bands to enable

spring activation and a distalization force (**Fig. 3C**). While the treatment in mandibular arch continued simultaneously, the wire was upgraded and worked up to  $0.019'' \times 0.025''$  rectangular stainless steel wire. After 5 months and three activations, the space of 5 mm was gained on right side (**Fig. 3D**). The space available and status of the unerupted premolar was confirmed using an intraoral periapical (IOPA) radiograph of that region, which showed sufficient space for eruption of tooth (**Fig. 4B**). The passive spring was left intact in the space for space maintenance over 1 month period where spontaneous emergence of the right second premolar was seen. Following this, the assembly was removed, and oral prophylaxis was done (**Fig. 3E, F**). The maxillary arch was finished using a 0.014-inch stainless steel wire, while mandibular arch was left as such to allow for physiological eruption of teeth. Bonded lingual retainer extending from canine to canine was given in maxillary arch for retention phase (**Fig. 5A-E**). The patient reported after 1 year of follow-up with considerably stable occlusion and maintained molar and canine relations (**Fig. 6A-E**).

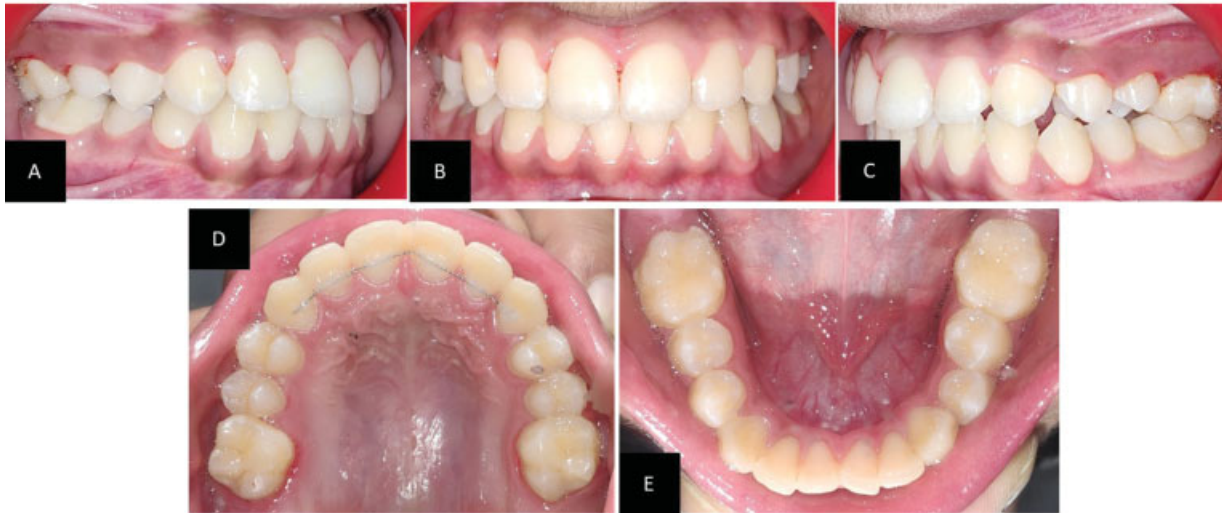## Discussion

Premature loss of primary teeth results in space loss and loss of arch dimensions. Space regaining appliances are considerably less cumbersome and employ simpler techniques to intercept the malocclusion.<sup>7</sup> In the present case, we used a modified lingual arch NiTi open coil space regainer, commonly referred to as King Appliance.<sup>8</sup> Although the appliance was formulated a few decades ago, its use in literature was found to be considerably scarce. Use of King Appliance was preferred over other treatment modalities, as this appliance is a fixed regainer; hence, patient compliance was good. Moreover, light continuous forces employed by the spring causes more bodily movement of the tooth in comparison to mere tipping of the

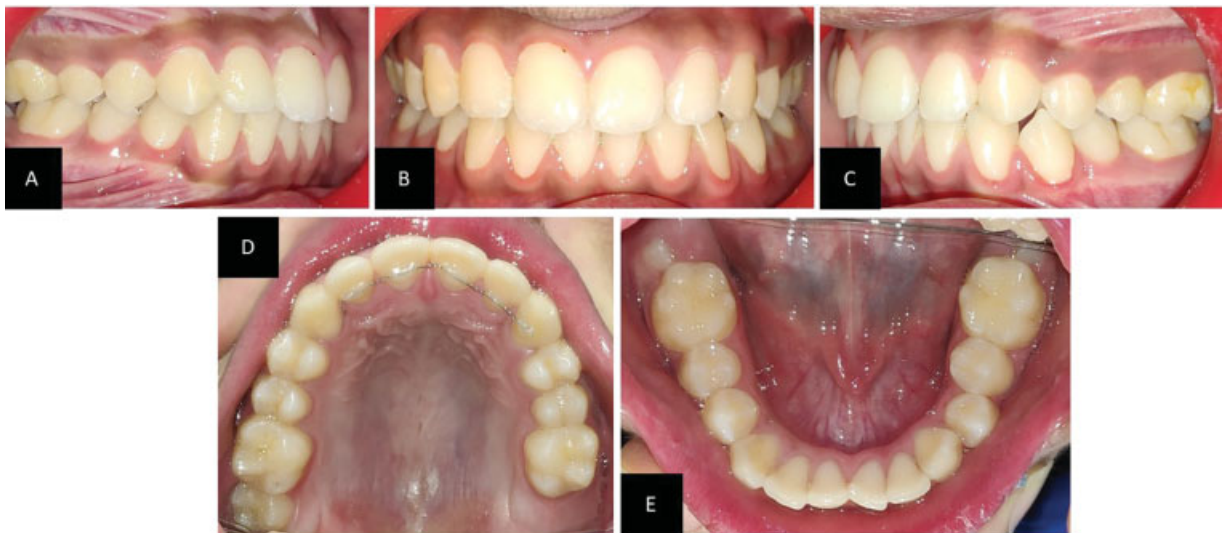

**Fig. 4** (A) Intraoral periapical (IOPA) radiograph of blocked mandibular right second premolar. (B) IOPAR shows sufficient space postspace regaining therapy.





**Fig. 5** (A) Posttreatment right lateral view shows Angle's class I molar relation with erupting premolars (B, C) Posttreatment view shows corrected overbite and reduced midline shift. (D, E) Occlusal views of maxillary and mandibular arches.



**Fig. 6** (A) After 1-year follow-up right lateral view shows stable molar and premolar relations with normal overjet and overbite. (B) Intraoral frontal view (C) Left lateral view with stable molar and premolar relations (D, E) Occlusal view shows erupting second molars in both the arches.

teeth. Some limitations of this appliance included gingival inflammation and secondary caries, undermining the banded tooth surface, due to difficulty in establishing a self-cleansable area.<sup>9</sup> The appliance employs the use of NiTi open coil springs that deliver consistent force in the range of 100 to 150 g. During activation, initially load increases linearly as a function of displacement by up to 3 mm and then it increases nonlinearly up to 11mm at which point the rise was rather exponential. NiTi coils exhibit a long range of superelasticity with minimum load fluctuation despite large deflection due to excellent spring back and superelasticity.<sup>4</sup> Due to this property, it is possible to achieve large tooth movements without having to replace the springs.

In the present case, 5 mm of space was regained over 5 months interval. This result falls in line with the case

discussed by Kisling and Hoffding<sup>3</sup> in which it was described that a millimeter a month is satisfactory progress in repositioning of first molar. It is also recommended when a molar relation of Angle's class I or a cusp-to-cusp molar relation is achieved, conventional space maintainer can be given until eruption of the tooth occurs. Case report by Jaikaria et al<sup>10</sup> describes a similar appliance, in which successful regaining of 4mm of space occurred over 2 months period of time. Chalakkal et al<sup>11</sup> described a new design of modified lingual arch with NiTi open coil spring, which was referred to as lingual arch crossbow and in which the assembly functions in such a manner that a mesially migrated first premolar can be distalized, using the crossbow, while open coil springs can work in a traditional manner to gain space conventionally.

## Conclusion

Intercepting a developing malocclusion prevents its progression into a more complicated dentoskeletal problem. In later stages of treatment, these malocclusions require extensive and complicated treatment planning. The current case described the use of less complicated orthodontic appliance, which was used successfully to correct developing malocclusion in comparably lesser period of time and at an adolescent stage of development.

### Conflict of Interest

None declared.

## References

- 1 Proffit W. Contemporary Orthodontics. 2nd ed. St. Louis, Missouri: Mosby Year Book; 1992
- 2 Gowri Shankar S. Textbook of Orthodontics. 1st ed. Philadelphia, Pennsylvania: Jaypee Brothers; 2011
- 3 Kisling E, Høffding J. Premature loss of primary teeth: part III, drifting patterns for different types of teeth after loss of adjoining teeth. ASDC J Dent Child 1979;46(01):34–38
- 4 Chandak P, Baliga S, Thosar N. Space regainers in pediatric dentistry. Int Dent Med J Adv Res. 2015;1:1–5
- 5 Civjan S, Huget EF, DeSimon LB. Potential applications of certain nickel-titanium (nitinol) alloys. J Dent Res 1975;54(01):89–96
- 6 Agarwal DK, Razdan A, Agarwal A, Bhattacharya P, Gupta A, Kapoor DN. A Comparative Study of Orthodontic Coil Springs. J Indian Orthod Soc 2011;45(04):160–168
- 7 Bishara S. Textbook of Orthodontics. 2nd ed. Philadelphia, Pennsylvania: Elsevier; 2001
- 8 Muthu MS. Paediatric Dentistry: Principles and Practice. 2nd ed. India: Elsevier; 2011
- 9 Negi KS. NiTi bonded space regainer/maintainer. J Indian Soc Pedod Prev Dent 2010;28(02):113–115
- 10 Jaikaria A, Negi P, Kukreja S. Use of open NITI Coil fixed space regainer: a case report. Int J Appl Dent Sci. 2019;5(04):280–282
- 11 Chalakkal P, Thomas AM, Akkara F, Pavaskar R. New design space regainers: 'lingual arch crossbow' and 'double banded space regainer'. J Indian Soc Pedod Prev Dent 2012;30(02):161–165